

The effect of Fenugreek on some biochemical parameters and histological structure of the liver in male rats induced diabetes by alloxan.

wedyanmarzh1983@gmail.com

Wedyan Merzah obeid¹

Pure Science College, Wasit University, Iraq

afayadh@uowasit.edu.iq

Ali Fayadh Bargooth²

Pure Science College, Wasit University, Iraq

Abstract

Millions of diabetics use herbal medicine for economic and cultural reasons. The objective of the present study was to explore of the effects of fenugreek in experimental diabetic (albino) male rats induced by alloxan measuring the level of liver enzymes Alanine transaminase, Aspartate aminotransferase and studying histological changes in the liver. The study included 40 rats divided into four groups (10 for each group) with weights ranging from 200-250mg, the first group was as a control group, the second group was injected with alloxan 120 /kg/b.w and nicotinamide 50 0.5 mg/kg/B.W. The third diabetic group received treatment with 50 mg/kg/b.w. of fenugreek. The fourth diabetic group received treatment with 100 mg/kg/B.W. of fenugreek, The animals were scarified and the heart's blood was extracted, where the serum was isolated to study the biochemical parameters of liver enzymes, the liver was removed and placed in 10% formalin solution for the histological study purpose of conducting the histological study. The study's findings demonstrated an increase in the effectiveness of liver enzymes as a result of the injection of alloxan, but after treatment with fenugreek, the level of these enzymes decreased in the third and fourth groups and also demonstrated that induction of diabetes caused changes in the rats livers, as it showed congestion of blood vessels in the hepatic central vein, necrosis of hepatocytes, irregular sinusoids, and thickening of the nuclei in diabetic group.

Keywords: Fenugreek, GOT, GPT, Histological.

1 Introduction

Diabetes is one of the common diseases of the age and one of the causes of death and disability in the world. The World Health Organization has defined diabetes as an imbalance in metabolic processes as a result of many pathogens, which are characterized by hyperglycemia

with a disturbance in the metabolism of carbohydrates, fats and proteins that occur as a result of a defect in the secretion of the hormone insulin or the action of insulin or both [1]. According to reports issued by the World Health Organization for the year 2017, there are approximately 171 million people suffering from diabetes, and this number is expected to increase to 360 million people worldwide in 2030 [2].

Type 1 insulin-dependent diabetes and type 2 non-insulin-dependent diabetes are the two basic kinds of diabetes mellitus, in addition to other types. The cause of infection with these types may be attributed to genetic disorders, that diseases that affect the pancreas gland lead to hormonal imbalance, as the use of drugs and chemicals often leads to the emergence of many infections and disorders of the immune system [3]. Chronic rise in diabetes during diabetes leads to many biochemical and structural changes in cells, tissues and organs of the body, and these changes explain the wide complications of diabetes, which can occur in many organs of the body such as kidneys, eyes, nerves and blood vessels[4]. Many researchers have indicated that reducing or stopping these complications depends primarily on the extent to which the level of diabetes is controlled and made close to normal, and thus many blood sugar-lowering drugs have appeared in addition to insulin, which is more common. However, the use of drugs showed a number of side effects, such as hypoglycemia when used in high doses, problems related to the liver and kidneys, cases of diarrhea, etc [5]. Therefore, there was a need to search for safer materials with fewer side effects, so that they could be used for a long time.

Fenugreek is one of the herbal medicinal plants that are very popular in India, Africa and Central Asia[6]. where it is used to treat many diseases, including diabetes, because it has antioxidants, antibacterials and fungi, and lowers blood fats [7]. The pharmacological effects of fenugreek are accredited to a group of bioactive substances include lipids, saponins, flavonoids, fiber, and polyphenols and amino acids. Diosgenin is the most active saponin of fenugreek, as it has a role in improving diabetes by several mechanisms [8]. and these mechanisms include regeneration of beta cells and stimulation of insulin secretion. Besides, yosgenin raises mRNA transcripts. Another active ingredient in fenugreek is the amino acid 4-hydroxyisoleucine, which stimulates insulin secretion and decreases total cholesterol and plasma triglycerides. About 45–60% of the carbohydrates in fenugreek seeds are called galactomannan. It has been shown to inhibit the hydrolysis enzymes of carbohydrates and fats in the digestive system, which leads to a lowering of postprandial glucose levels[9]. Due to the lack of studies on this type of important medicinal plants (fenugreek), the current study was planned, which aims to demonstrate the effect of

fenugreek on the histological and structures of the liver of laboratory adult male rats in which diabetes is induced and knowing the preventive effect on it, including:

1. Investigating the effects of oral consumption of fenugreek on histological structures of Liver in alloxan-induced diabetic male rats.
2. Showing the preventive effects of fenugreek (*Trigonella foenum-graecum*) against type 2 diabetics in male rats, by measuring ALT and AST

2 Materials and methods

2.1 The experimental animals

In this investigation, 40 healthy male rats weighing between 200 -250g were used. Prior to the start of the trial, the animals had a one-week acclimatization period. The animals were kept in conventional conditions both before and during the experiment, with a temperature of $22 \pm 2^{\circ}\text{C}$ and a consistent 12/12 h light-dark cycle. Standard pellets and unlimited tap water were made available to the rats without restriction.

2.2 Induction of type 2 diabetes

After a 12-hour overnight fast, the rats received an intraperitoneal injection of freshly produced alloxan monohydrate and nicotina-mide (Sigma, USA; 120 +50 mg/kg b.w.) to cause type 2 diabetic mellitus. In regular saline. Animals were deemed diabetic and chosen for the following studies after 72 hours if their fasting blood glucose levels were greater than 200 mg/dL. [10].

2.3 Dosing Preparation

Preparation dosing of 50mg/kg of fenugreek; 180mg of fenugreek seed powder was dissolved in 9 ml of distilled water to obtain a concentration of 20mg/ml, then the solution was administered orally by stomach tube as 0.5ml/kg of B.W.

Preparation dosing of 100mg/kg of fenugreek; 360mg of fenugreek seed powder was dissolved in 9 ml of distilled water to obtain a concentration of 40mg/ml, then the solution was administered orally by stomach tube as 0.5ml/kg of B.W. [11].

2.4 The Experimental design

The animals were divided into four groups of ten rats at random as follows:

The first group was as a control group received distal water, the second group was injected with alloxan 120 /kg/b.w and nicotinamide 50 mg/kg/B.W without treatment. The third diabetic group received treatment with 50 mg/kg/b.w. of fenugreek. The fourth diabetic group received treatment with 100 mg/kg/B.W. of fenugreek,

2.5 Collection of Blood Samples and tissue

Blood samples were obtained by heart puncture; by using test tubes with no anticoagulant and blood samples were collected to allowable standup and coagulating. Serums were separated from coagulated blood samples by centrifuge at 1000 round per minute (rpm) for 15 min, then samples of serum were kept in a freezer at -20°C for the purpose to measuring the level of liver GOT,GPT by Elisa according to commercial kits instructions (MyBioSource USA),and Scarifying animals were done by chloroform,the scarifications were performed and the targeted organs was collected (liver) and tissue were dissected and cleaned, then preserved in 10% of neutral buffered formalin for histological study using H&E stain.

The Statistical Analysis System- SAS (2012) program was used to detect the effect of difference factors in study parameters. Least significant difference (LSD) test and Analysis of Variation (ANOVA) were used to statistical compare between means of obtained results.

3 Results and Discussions

3.1 Liver functions . When compared to the negative control group, the levels of the enzymes alanine aminotransferase (ALT/GPT) and aspartate aminotrans-ferase (AST/GOT) were significantly higher in diabetic rats ($P \leq 0.01$). AST and ALT values were significantly ($P \leq 0.01$) lower (after fenugreek administration) compared to the diabetes control group according Table-1

Table(1): Liver enzyme U/L in induced diabetic rats groups dosed orally during the thirty days of experiment

Parameters	Mean \pm SE				SD value
	C-ve	G+ve	T1 (50)	T2 (100)	
ALT/GPT (U/L)	4.4 ± 1.74 c	7.2 ± 8.83 a	9.8 ± 2.57 b	2.6 ± 1.84 c	26.95 **

AST/GOT (U/L)	5.4 ± 3.89 b	2.6 ± 11.05 a	7.8 ± 5.98 b	7.8 ± 3.41 b	41.63 **
ing with the different letters in same row differed significantly; ** (P≤0.01)					

C-ve: Negative control rats received distilled water, with normal diet.

C+ve: Positive control diabetic rats injected a single dose of alloxan 120mg/kg,i.p and nicotinamide 50mg/kg/BW without treatment.

T1 (50): Diabetic rats that treated orally with fenugreek at a dose of 50 mg/kg /B.W.

T2 (100): Diabetic rats that treated orally with fenugreek at a dose of 100 mg/kg /B.W.

3.2 Histological study in the liver: The liver of the negative control group underwent histological investigation, which revealed a normal control rat liver with a central vein, liver cords of hepatocytes extending from the vein, and blood sinusoids separating them. Hepatocytes have rounder nuclei when they first developed. (**Figure 1**).

The histological results of the liver of rats after intraperitoneal injection with a single dose of alloxan (120 mg/kg / B,W) followed by nicotinamide (50 mg/kg / B.W) showed high numbers of degenerated hepatocytes with necrosis appeared pyknotic, karyohexsis and dilatation of central vein with dilation of sinusoids and congestion of blood vessels (**Figure2,3,4**)

When compared to the diabetic group not receiving treatment, the protective treatment with fenugreek (50 mg/ kg/ B.W.) showed a decrease in the histological alterations in the liver, there was less expansion of the central vein, sinusoidal gaps, congestion in the central vein, and lymphocyte infiltration. (**Figures 5,6**)

The histological results of fenugreek (100 mg/kg/B.W.) treatment of alloxan diabetic rats resulted in nearly normal hepatostructure with radially oriented hepatocytes surrounding the central vein and the lack of any degenerated cells. Similar to the normal control group, the hepatic sinusoidal spaces and von Kupffer cells were present. (**Figures 7,8**)

The results of the current study showed that GPT and GOT levels in the serum of male albino rats increased after alloxan-induced diabetic mellitus, which is consistent with the study's findings [12, 13, 14] that the reason for this increase may be due to damage to the membranes of hepatocytes due to increased lipid peroxidation and an increase in the concentration of free radicals resulting from diabetes mellitus, which leads to the leakage of enzymes into the blood serum [15]. Alloxan may have a role in increasing hepatic necrosis and damage to hepatocytes, which gives evidence of the high toxicity of alloxan and the liver attempts to remove the alloxan toxicity, as in this case, the enzymes rises of GPT and GOT is consistent with those indicated by other studies[16, 17] . These two enzymes may have increased levels due to the hepatocytes

growing larger and the endoplasmic reticulum being stimulated to manufacture more of the enzyme to accommodate the growth of the cell [18]. It may be attributed to the fact that alloxan increased blood sugar, leading to increased oxidative stress and the formation of ROS, which led to oxidation and necrosis of fats in the membranes of liver cells, which led to an increase in the effectiveness of these enzymes in the liver[19]

The present study, fenugreek treatment led to a significant decrease in activity of the two enzymes AST, AST compared to the control group, this result is similar to the result of [20], who found that this decline is probably due to the fenugreek containing the amino acid 4-hydroxyisoleucine which improves the secretion of insulin, which has a role in reducing the level of glucose in the blood by stimulating cells to take advantage of the sugar present in the blood then improve the metabolic processes of cells, reduce oxidative stress and protect the membranes of liver cells from degeneration or this improvement is attributed to the effective role of fenugreek in curbing the action of free radicals and reducing lipid oxidation because it contains antioxidants, thus preserving the membranes of liver cells from breakdown and reducing The release of enzymes into the blood serum[21]. Histologically, when compared to the rats in the negative control group, the white male rats with diabetes underwent changes to their livers., which is in agreement with other studies conducted on rats [22, 23], whom claimed that the sinusoids slightly expand as a result of the high blood glucose caused by the injection of alloxan, it also includes the appearance of multiple areas of inflammation and areas of cytoplasmic eruption, and which may be brought on by inadequate venous flow at the level of the hepatic vein or inferior vena cava and the reason why liver cells become damaged, whether it is due to immunological factors or the toxicity of alloxan. Oxidative stress resulting from the accumulation of free radicals causes the destruction of hepatocytes as well as lipid peroxidation of the cell membranes or mitochondrial membranes, causing the emergence of an inflammatory and immune response[24]. Blood congestion was also observed in some areas, caused by poor blood drainage as a result of hepatic venous obstruction, causing cessation or disruption of blood flow through the hepatocytes, and this is what [25], noted of the occurrence of blood congestion in diabetes. After the treatment with the aqueous solution of the fenugreek plant, the doses were 50 and 100 mg/kg/B.W, a significant improvement in liver tissue, In particular at 100 mg/kg/B.W., a high dose compared to the positive group, and this result was identical to [26], who showed that the aqueous solution of the fenugreek plant showed normal liver tissues. Liver enzymes, which confirms the role of the plant in protecting the liver, which is due to the presence of flavonoids compounds, as they have the ability to curb the action of free radicals resulting from alloxan and reduce the lipid peroxidation the liver membranes, thus preserving the membranes of hepatocytes as metabolic cells and reducing damage to the liver, considering that the fenugreek contains components that act as antioxidants .In conclusion, the present study was designed to compare the effect of two doses of fenugreek seed on histopathological effects of liver and some parameters including liver function. Fenugreek may represent candidate alternative treatment to control diabetes mellitus and its related hepatopathy.

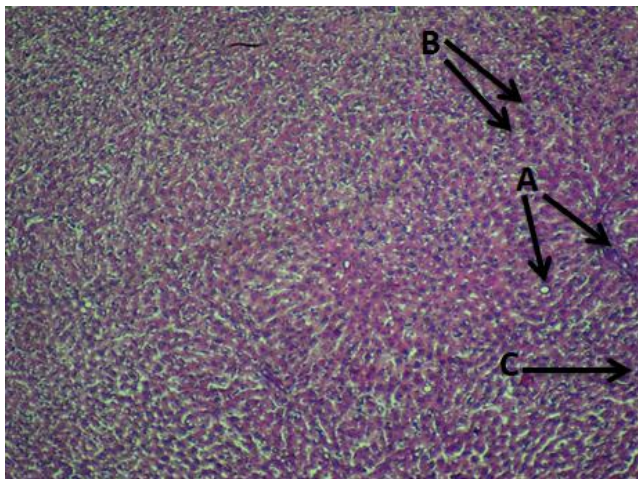


Figure (1): Control group Cve- of male rat liver showed a normal central vein (A), normal hepatocytes (B), and normal sinusoids (C). H&E, 40x

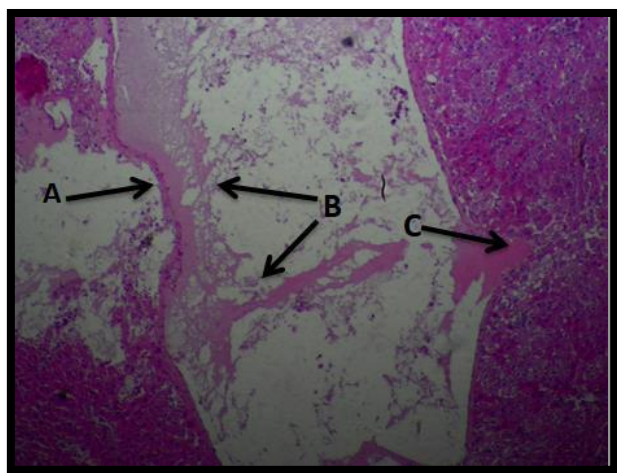


Figure (2): Liver of male rat exposed to single dose of alloxan (120 mg/kg/B.W) and nicotinamide (50 mg/kg/B.W) of positive group, showed high dilation of central vein (A), high congestion in central vein (B), hemorrhage in liver tissue (C). H & E, 40x

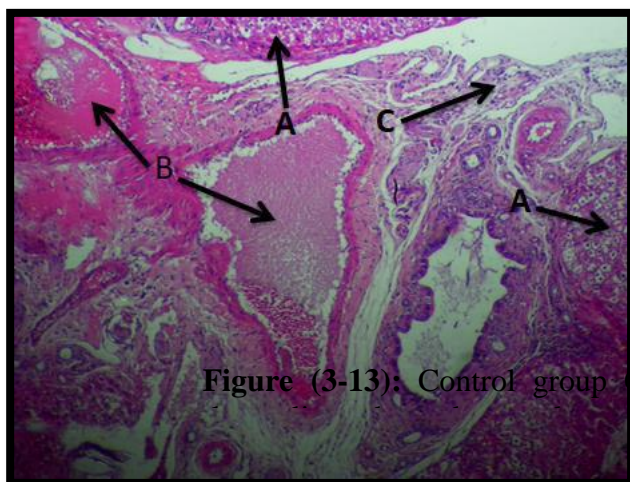
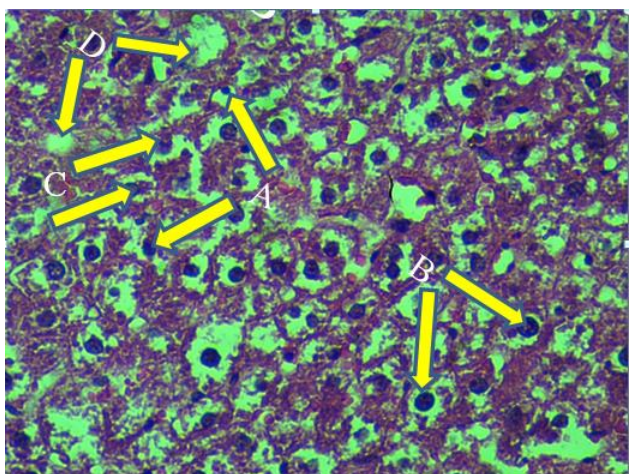


Figure (3-13): Control group Cve- of

Figure (3): Liver of male rat exposed to single dose of alloxan (120 mg/kg/B.W) and nicotinamide (50 mg/kg/B.W) of positive group, showed destruction of liver tissue (A), high congestion of blood vessels in the septa (B), infiltration of lymphocyte (C). H & E, 40x



Figure(4): Liver of male rat exposed to single dose of alloxan (120 mg/kg/B.W) and nicotinamide (50 mg/kg/B.W) of positive group Cve+ showed degeneration of hepatocyte (A), pyknotic cell (B), karyohexis cell (C), karyolysis (D). H & E, 400X

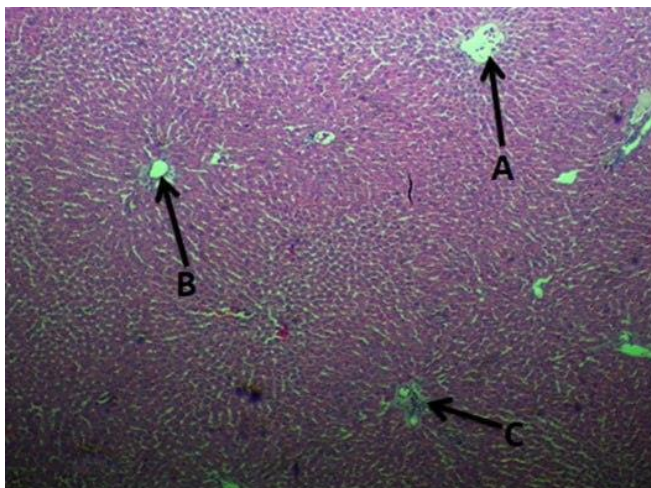


Figure (5): Liver of male rat group treatment of fenugreek (50 mg/kg /B.W) T1, showed less disturbance of liver architecture, less dilation of central vein (A), less congestion in the central vein (B), less congestion in the blood vessels of connective tissue (C). H & E, 40x

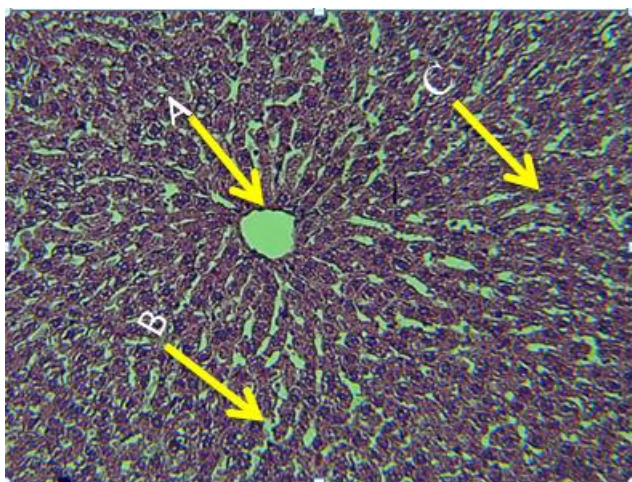


Figure (6): Liver of treatment group of fenugreek (50 mg/kg / B.W) T1, showed less expansion of central vein without congestion (A), less expansion of sinusoidal spaces (B), less necrosis and degeneration of hepatocytes and there were no hemorrhage (C). H & E 20x

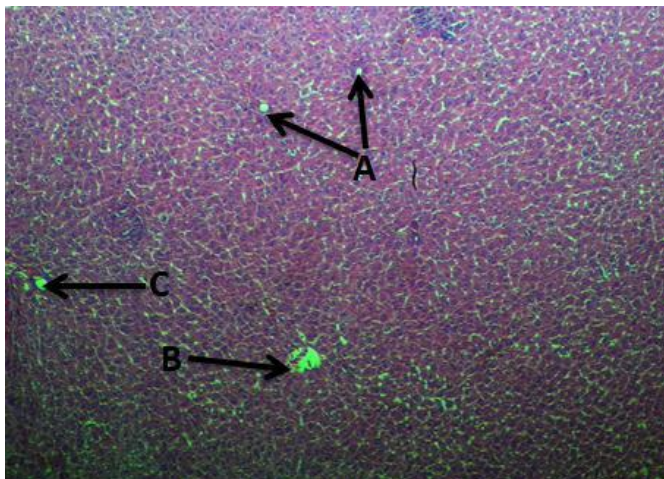


Figure (7): Liver of treatment group of fenugreek (100 mg/kg/ B.W) T2, showed normal central vein in some area of liver tissue (A), decrease in dilation of central vein in some area of the tissue (B), decrease in congestion of central vein & blood vessels of septa (C). H & E, 40x

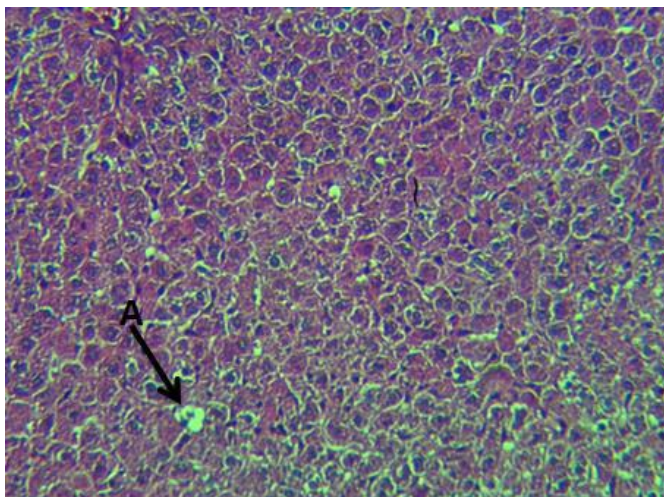


Figure (8): Liver of treatment group of fenugreek (100 mg/kg/ B.W) T2, showed nearly normal architecture of liver tissue, there were absent of less necrosis and degeneration hepatocyte, there were absent congestion and hemorrhage, normal central vein (A). H & E, 20x

4 References:

- [1] J.Tuomilehto, "Definitions of intermediate hyperglycaemia and progression to type 2 diabetes" *The Lancet Diabetes & Endocrinology*, vol. 7, no. (4), Pp. 243-245,(2019).
- [2] S. Abdoli, D.H Jones., A.Vora. & H. Stuckey, " Improving Diabetes Care: Should We Reconceptualize Diabetes Burnout" *The Diabetes Educator*, vol. 45,no (2), Pp. 214-224, (2019).
- [3] S. M. Genuth., J. P Palmer., and D. M. Nathan., "Classification and diagnosis of diabetes". *Diabetes care*, 36(1), s 67, (2021).
- [4] Q.-Q Yang,, J.-W Sun,,D Shao.,H.-H Zhang.,C.F Bai, and F.-L Cao, "The Association between Diabetes Complications, Diabetes Distress, and Depressive Symptoms in Patients with Type 2 Diabetes Mellitus". *Clinical Nursing Research*, 30, 293-301,(2021)
- [5] M ,Ustinova," Novel susceptibility loci identified in a genome-wide association study of type 2 diabetes complications in population of Latvia". *BMC medical genomics*, 14, 1-11,(2021).
- [6] E. Basch, C. Ulbricht, G. Kuo, P. Szapary and M. Smith," Therapeutic applications of fenugreek". *Altern Med Rev* 8: 20-27, 2003.
- [7] K.C. Nagulapalli Venkata, A. Swaroop D. Bagchi and A. Bishayee " A small plant with big benefits: Fenugreek (*Trigonella foenumgraecum* Linn.) for disease prvention and health promotion". *Mol Nutr Food Res* 61: 1600950, 2017.
- [8] N. Naicker, S. Nagiah, A. Phulukdaree & A. Chuturgoon, " *Trigonella foenum-graecum* seed extract, 4-hydroxyisoleucine, and metformin stimulate proximal insulin signaling and increase expression of glycogenic enzymes and GLUT2 in HepG2 cells". *Metab Syndr Relat Disord* 14: 114-120, 2016
- [9] A. Ota & N.P. Ulrih," An overview of herbal products and secondary metabolites used for management of type two diabetes". *Front Pharmacol* 8: 436, 2017.
- [10] K. K. Vattam, H. R.. B. Raghavendran,, M. R Murali,, H Savatey, & T Kamarul, " Coadministration of alloxan and nicotinamide in rats produ esbiochemical changes in blood and pathological alterations comparable to the changes in type II diabetes mellitus". *Human and experimental toxicology*, 35(8), 893-901, (2016).
- [11] M.E. Baset, T. I. Ali, H. Elshamy, A.M. El Sadek, D.G. Sami, T.M. Badawy, &A. Abdellatif,' Anti-diabetic effects of fenugreek (*Trigonellafoenum-graecum*): A comparison between oral and intraperitoneal administration-an animal study". *International journal of functional nutrition*,vol.1 no. (1),Pp 1-1,2020.

- [12] J.D. Kim ,S.M. Kang., B.I. Seo H.Y. Choi & S.K. Ku, "Anti-diabetic activity of SMK001a poly herbal formula in streptozotocin induced diabetic rats: therapeutic study". *Biol. Pharm.Bull.* 29, 477-482,2006
- [13] Z Kechrid , Z Amamra, , F.Dahdouh,. and N Bouzerna,"*The Effect ofCaNa2- EDTA on Metabolism of Zinc and Carbohydrate as well as Some Biochemical Factors in Experimental Diabetes*". *Iranian J. Publ.Health.*,vol.36no (1),Pp. 15-21,2007
- [14] F. Ani, I. Ime, J. Atangwho, H. I. Edisua, A. I Mary& U. E. Essien," Effect of traditional diets on oxidative stress and lipid profile of alloxaninduced diabetic rats". *African ,J. Food, Sci.*vol. 5,no(3), Pp143-147,2011.
- [15] I. M. Al-Hazza, , S. A Ibrahim, , S. A Bashandy,. and S. A. Alshehry, "Protective Effect of Vitamin B6 Against Carbon Tetrachloride Induced Hepatotoxicity in Male Rats. Effect on Liver enzymes, Glucose, Total protein, and Insulin hormone". *Saudi J. Biol. Sci.*,vol. 15no. (3),Pp 75-83,2008
- [16] , S.A. Sakr, & S.A Gabr, "Long-term effects of chlordane on the tissues of rabbits. Histological changes in the liver". *J. Egypt. Ger. Soc. Zool.*,(07c):Pp 319-329.,1992
- [17] NRAVC, "Australia. toxicological end points used for human risk assessment". *National Registration Authority for Agricultural and Veterinary chemicals.* 134605 :Pp 64 – 4,2002.
- [18] A.C. Ene, E.A. Nwankwo, L. M. Samdi , "Alloxan-Induced Diabetes in Rats and the Effects of Black Caraway (Carum carvi L.) Oil on Their Body Weight". *Res. J.Medicine and Med. Sci.*,vol. 2, no.(2),Pp 48-52,2007
- [19] F. K. Alharbi& M. S. Hanan,"Influence of dietary supplementation of Garden cress (*Lepidium sativum* L.) on histopathology and serum biochemistry in Diabetic Rats". *Egyptian Journal of Chemistry and Environmental Health* vol.3,no.,Pp 1-19,2017
- [20] M. R. Haeri, M. Izaddoost, M. R.. S. Ardekani, M. R., Nobar& K. N White, "The effect of fenugreek 4-hydroxyisoleucine on liver function biomarkers and glucose in diabetic and fructose- fed rats". *Phytotherapy Research: An International Journal Devoted to Pharmacological and Toxicological Evaluation of Natural Product Derivatives* vol. 23 no.(1),Pp 61-64,2009
- [21] C. Broca,R..Gross, P. Petit, Y. Sauvaire, M. Manteghetti, M. Tournier, P Masiello, R. Gomiis, G. Ribes, "4-Hydroxyisoleucine: Experimental evidence of its insulintropic and antidiabetic properties". *Am. J. Physiol.* 1999, 277, E617–E623. [Google Scholar] [PubMed]
- [22] M . A . H . AL-Joubori ."*Histological and Cytological Effects of Some Plants Extracts on Hyperglycemic Male Rats*". Ph.D. thesis. College of Science University of Babylon.Iraq, 2012

[23] A.H .Al-Safi. "*Effect diabetes induced on some functional and histological parameters in pregnant females and white born in the white rats*" a master thesis (unpublished). Karbala University - College of Education for Pure Sciences - Department of Life Sciences.Iraq,2013

[24] A.S.Magumdal, M.N,Saraf, N.R, Andrades. R.Y.Kamble. "Preliminary studies on the antioxidant activity of Tribulusterrestris and Eclipta alba". *Phcog. Mag* vol.4, no.(13), Pp102-107.2008

[25]D,Q,A, Al-Tamimi. "*Effect of the alcoholic extract of leave vinca rosea plant in some functional and histological on males albino rats treated with alloxan experimentally*". Master's thesis Karbala University-College of Education for pure Sciences-Department of Life Sciences.Iraq, 2014

[26] E. A. Khalil."Biochemical and histopathological studies on the influence of aqueous extract of fenugreek seed (Trigonellafoenumgraecum) on alloxan diabetic male rats". *The Egyptian Journal of Hospital Medicine*,vol. 15, no.(1),Pp 83-94,2004